

Experimental Osteomyelitis Treatment With Antibiotic-Impregnated Hydroxyapatite

Mark E. Shirliff, PhD;* *Jason H. Calhoun, MD‡;*
*and Jon T. Mader, MD**,†*

A calcium hydroxyapatite antibiotic implant was evaluated to determine its efficacy as an antibiotic delivery system in a localized osteomyelitis rabbit model. Localized rabbit tibial osteomyelitis was developed with an intramedullary injection of methicillin resistant *Staphylococcus aureus*. Infected rabbits were randomized and divided into eight groups depending on treatment with or without debridement, systemic antibiotics, antibiotic-impregnated polymethylmethacrylate beads, or calcium hydroxyapatite implants with and without antibiotic impregnation. All treatments began 2 weeks after infection. After 4 weeks of therapy, the involved bones were cultured for concentrations of *Staphylococcus aureus* per gram of bone. Rabbits (n = 11) that had calcium hydroxyapatite (impregnated with vancomycin) implanted into the dead space after the debridement surgery had

an 81.8% infection clearance after treatment. Rabbits (n = 10) that had polymethylmethacrylate beads (impregnated with vancomycin) implanted into the dead space after debridement surgery had a 70% clearance rate. All other treatment modalities resulted in less than 50% clearance rates. Calcium hydroxyapatite may be an effective alternative to polymethylmethacrylate for providing local antibiotic therapy in cases of methicillin resistant *Staphylococcus aureus* osteomyelitis.

From the *Center for Biofilm Engineering, Montana State University, Bozeman, MT; and the **The Marine Biomedical Institute, the †Division of Infectious Diseases, Department of Internal Medicine, and the ‡Department of Orthopaedic Surgery, The University of Texas Medical Branch, Galveston, TX.

This research was sponsored by a grant from Osteogenics Incorporated.

Reprint requests to Mark E. Shirliff, PhD, Center for Biofilm Engineering, 366 EPS Building, PO Box 173980, Montana State University, Bozeman, MT 59717-3980.

Received: November 3, 2000.

Revised: November 7, 2001.

Accepted: December 20, 2001.

Implant materials impregnated with antibiotics have long been used to manage the dead space created by debridement surgery in patients with osteomyelitis.^{2,14,19} By providing local, sustained, and high concentrations of antimicrobial agents to the area of infection, the eradication or suppression of the infectious process is assisted.^{3,14,18,40–43} Also, this high concentration of antibiotic can be attained without systemically exposing an individual to antibiotic levels that often would result in numerous toxic side effects.^{14,35,42}

Polymethylmethacrylate, one example of a widely used implant material in orthopaedics, has been used successfully with numerous antibiotics, including vancomycin, tobramycin, and gentamicin.^{17,18,29,30} Various problems have been associated with polymethylmethacrylate

use, including the requirement for bead removal by a second surgical procedure and poor antibiotic elution properties.^{1,4,23,44} In addition, this implant material may cause local immune compromise according to *in vitro* studies.^{16,31–34} However, the clinical significance of these studies has not been confirmed.

A new implant material may be able to reduce or eliminate many of the problems associated with the clinical standard of polymethylmethacrylate bead therapy for dead space management. One biodegradable material that has been used clinically includes the gentamicin-impregnated collagen sponge.³⁸ However, recent evidence has shown that antibiotic release may last only 4 days.³⁹ Numerous *in vitro* and *in vivo* studies have been done that use alternative materials for possible implantation. Kanellakopoulou and Giannellos-Bourboulis¹⁹ did a review of carrier systems. A calcium hydroxyapatite material impregnated with antibiotics may be an effective alternative to polymethylmethacrylate and intravenous antibiotics. Average compact bone is composed of approximately 30% matrix (collagen) and 70% salts, the majority of which is calcium hydroxyapatite. This salt material may be more effective than current treatment modalities for various reasons. First, this material could provide bactericidal concentrations of antibiotics for the prolonged time necessary to completely treat the particular orthopaedic infection. Second, because the hydroxyapatite material is resorbed, there is no need for bead removal such as in the case of polymethylmethacrylate-antibiotic impregnated beads. Third, variable resorbability from weeks to months because of bead size may allow many types of infections to be treated. Finally, because the hydroxyapatite material is replaced slowly by new-forming bone, the soft tissue or bone defect may slowly fill with tissue and eliminate the need for reconstruction.

Calcium hydroxyapatite was evaluated *in vivo* by Korkusuz et al²⁰ in a rat osteomyelitis model who found that eradication of infection occurred within 7 weeks of implantation with antibiotic-impregnated calcium hydroxyapatite ceramic composites. In another study, Cornell

et al⁶ used hydroxyapatite ceramic beads impregnated with gentamicin sulfate and gentamicin crobefat (a low water solubility salt of gentamicin) to treat experimental osteomyelitis in rabbits. They found treatment with antibiotic-impregnated calcium hydroxyapatite cleared *Staphylococcus aureus* infection in 72.7% of the animals. Most recently, a study that compared the efficacy between a biodegradable implant and polymethylmethacrylate was done by Solberg et al³⁷ in an experimental osteomyelitis rat model. They found that bacterial clearance rates were equal between animals treated with gentamicin-impregnated polymethylmethacrylate and gentamicin-impregnated calcium hydroxyapatite implants. Although showing the efficacy of calcium hydroxyapatite as a delivery vehicle for gentamicin in the treatment of methicillin sensitive *Staphylococcus aureus* osteomyelitis, the results from these studies may not be applicable to osteomyelitis attributable to methicillin resistant strains of this species.

Therefore, the objective of the current study was to determine whether an hydroxyapatite material impregnated with vancomycin had the potential of supplying a basis for bone reconstruction and providing an improved treatment method for the long-term delivery of antibiotics to methicillin resistant *Staphylococcus aureus* orthopaedic infections as tested in a rabbit model with localized osteomyelitis.

MATERIALS AND METHODS

A localized osteomyelitis was developed for the current study in 2 to 3 kg female New Zealand White rabbits. The localized osteomyelitis model was a combination of the dog model of Fitzgerald¹⁰ and the rabbit model of Mader²¹ and Shirliff and Mader.³⁶

Organism

The strain of *Staphylococcus aureus* was obtained from a patient with osteomyelitis who was receiving treatment. The isolate was a methicillin resistant *Staphylococcus aureus* strain. The organism had been stored at -70°C in defibrinated sheep's blood and was used as needed. Antibiotic tube dilution sensitivities of this *Staphylococcus aureus* strain were measured for vancomycin in a cation

supplemented Mueller-Hinton broth (Difco Laboratories, Detroit, MI).⁹

The minimum inhibitory concentration of vancomycin to *Staphylococcus aureus* was determined using an antibiotic tube-dilution method in cation supplemented Mueller-Hinton broth. Vancomycin was diluted serially; twofold, in tubes containing 5 mL of cation supplemented Mueller-Hinton broth. The *Staphylococcus aureus* inoculum for the series of tubes was 0.1 mL of 5×10^6 colony forming units per mL dilution in cation supplemented Mueller-Hinton broth of an overnight culture. The minimum inhibitory concentration was the lowest concentration of antibiotic that prevented turbidity after 20 hours incubation at 37° C. After the minimum inhibitory concentration was determined, 0.01 mL of each clear tube was streaked onto the surface of a blood agar plate. The minimum bactericidal concentration was the lowest concentration of antibiotic that results in 10 or fewer colony forming units on the plate after 24 hours incubation at 37° C.

Calcium Hydroxyapatite

The hydroxyapatite cement used in the current study was BoneSource (Osteogenics Inc, Richardson, TX). The antibiotic was added to the calcium hydroxyapatite before implantation by adding 4 g vancomycin to 40 g calcium hydroxyapatite powder.

Induction of Tibial Osteomyelitis

A localized *Staphylococcus aureus* osteomyelitis was induced surgically in the left lateral tibial metaphysis of all rabbits within all study groups.^{25,27,36}

Preparation of the Infective Media

One colony forming unit of *Staphylococcus aureus* was incubated overnight in cation supplemented

Mueller-Hinton broth at 37° C. The bacterial concentration of the culture was adjusted to 10^8 colony forming units per mL using a Petroff Hausser Counting Chamber (Fisher Scientific, Pittsburgh, PA). The culture was diluted additionally in 0.85% saline to a final concentration of 10^6 colony forming units per mL.

Animals and Infection Preparation

New Zealand White rabbits (Ray Nicholl's Rabbitry, Lumberton, TX), 8- to 12-weeks old and weighing approximately 2 kg (n = 110), were used for the study. After the mandatory 7-day wait after delivery to the on-site animal resources center, rabbits were anesthetized using an intramuscular injection of 45 mg/kg Ketaset (Fort Dodge Laboratories, Inc, Fort Dodge, IA) and 8 mg/kg Xylazine (Rugby Laboratories, Inc, Rockville Center, NY).

Infective Procedure

An 18-gauge needle then was inserted percutaneously through the lateral aspect of the left tibial metaphysis into the intramedullary cavity. Five percent sodium morrhuate (Eli Lilly, Indianapolis, IN) (0.15 mL), 0.1 mL *Staphylococcus aureus* (10^7 colony forming units/mL), and 0.2 mL sterile 0.85% saline were injected sequentially. The infection was allowed to progress for 2 weeks, at which time the severity of osteomyelitis was determined radiographically (Table 1).

Treatment Groups

At the end of 2 weeks after infection, 98 of the 110 infected rabbits had radiographically-confirmed localized proximal tibial osteomyelitis. These rabbits were separated into eight study groups; each group was sacrificed at 6 weeks after infection. Group One

TABLE 1. Gross Pathologic and Radiographic Criteria for Grading the Severity of Experimental *Staphylococcus Aureus* Osteomyelitis in Rabbits

Grade	Gross Pathologic Features	Grade	Radiographic Findings
0	Normal	0	Normal
1+	No bone involvement; soft tissue swelling at proximal tibial metaphysis	1+	Elevation or disruption of periosteum, or both; soft tissue swelling
2+	Soft tissue abscess; < 10% widening of proximal tibial metaphysis	2+	< 10% disruption of normal bone architecture
3+	> 10% widening of proximal tibial metaphysis	3+	10% to 40% disruption of normal bone architecture
4+	Disruption or pitting of bone architecture	4+	> 40% disruption of normal bone architecture

(n = 26) was comprised of rabbits that were infected but was left untreated for the duration of the study. Group Two (n = 12) was comprised of rabbits that had debridement surgery 2 weeks after infection. Group Three (n = 8) was comprised of rabbits that had debridement surgery 2 weeks after infection and 4 weeks subcutaneous vancomycin administration at a dose of 30 mg/kg twice daily. This dose was chosen based on previous studies with osteomyelitis in rabbits.^{22,45} Group Four (n = 11) included rabbits that had only 4 weeks of subcutaneous vancomycin administration at a dose of 30 mg/kg twice daily starting 2 weeks after infection. Rabbits in Group Five (n = 10) had the hydroxyapatite material (without antibiotic impregnation) implanted into the dead space created by the debridement surgery (done 2 weeks after infection). Rabbits in Group Six (n = 8) had hydroxyapatite material (without antibiotic impregnation) implanted into the debrided region and subcutaneous vancomycin treatment at a dose of 30 mg/kg twice daily for 28 days after debridement surgery. Rabbits in Group Seven (n = 12) had hydroxyapatite material (impregnated with vancomycin) implanted into the dead space left after the debridement surgery. Rabbits in Group Eight (n = 11) had 6 mm diameter polymethylmethacrylate beads (impregnated with vancomycin) implanted into the dead space after debridement surgery. A 4-week therapy period was required for each group (except Group One). At the end of 4 weeks of therapy, radiographs were obtained and compared with the radiographs obtained before treatment to evaluate the extent of osteomyelitis, the effect of therapy, and the bone growth.

Debridement of the Defect and Device Implantation

After the animals were assigned a treatment group, necrotic tissue was debrided from within the defect and from the surrounding soft tissue in all groups except Groups One and Four.³⁶ Depending on the group, plain or vancomycin-impregnated hydroxyapatite material or polymethylmethacrylate (6 mm diameter beads) was packed into the debrided defect of the rabbits. Approximately 2 to 7 g calcium hydroxyapatite cement were implanted into the dead space depending on the size of the defect after debridement. Treatment for the animals of each group lasted 28 days (42 days after infection), at which time the animals were sacrificed and all tibias were harvested for bone *Staphylococcus aureus* concentration determination.

Determination of Bacterial Concentration Per Gram of Bone

Quantitative counts of *Staphylococcus aureus* colony forming units per gram of tibial bone were determined for all study groups. After animals were sacrificed, the tibias were stripped free of all soft tissue, the proximal and distal ends of the tibias were removed, and the implant-containing marrow was separated carefully from the bone as a cohesive unit. The remaining bone was broken into large fragments, and all adhering bone marrow was removed. The large bone fragments were pulverized in a bone mill (Brinkmann Instruments, Westbury, NY) and the final product was weighed. Physiologic 0.85% saline was added to the pulverized bone in a 3:1 ratio (3 mL saline/g bone) and the suspension was vortexed for 5 minutes. Five, 10-fold dilutions of each of the saline-bone suspension were prepared with sterile 0.85% (weight to volume) NaCl solution. Twenty microliter samples of each of the five dilutions were spotted onto blood agar plates and incubated at 37°C for 24 hours. The minimum detectable concentration of bacteria was 50 colony forming units per gram of bone. Colony forming units then were counted for each tibia sample. The mean log of the colony forming units for the five plates and the mean *Staphylococcus aureus* concentration for each treatment group was calculated. The mean colony forming units for each group were compared using a Student's t test whereas a Fisher's exact test was used to compare groups based on percent infected. Only those probability values equal to or less than 0.05 were considered significant.

RESULTS

Minimum Inhibitory Concentrations and Minimum Bactericidal Concentrations

Isolates of *Staphylococcus aureus* obtained from rabbits still infected at the end of the treatment period were tested for antibiotic sensitivity to vancomycin. All isolates (including the original patient isolate) had minimum inhibitory concentration equal to or less than 0.39 µg/mL and minimum bactericidal concentration equal to or less than 0.79 µg/mL.

Bone Cultures

Treatment with antibiotic-containing calcium hydroxyapatite resulted in mean bone colony

forming unit levels of approximately 10^5 colony forming unit per gram of bone (Fig 1). This bacterial concentration did not show any statistically significant differences ($p > 0.05$) when compared with the bacterial concentrations in the control and other treatment groups. However, each group showed different rates

of reduction in *Staphylococcus aureus* concentration to undetectable levels (Fig 2).

The calcium hydroxyapatite showed significantly lower infection rates after treatment when compared with the other treatment modalities ($p \leq 0.05$) with the exception of the polymethylmethacrylate bead (impregnated

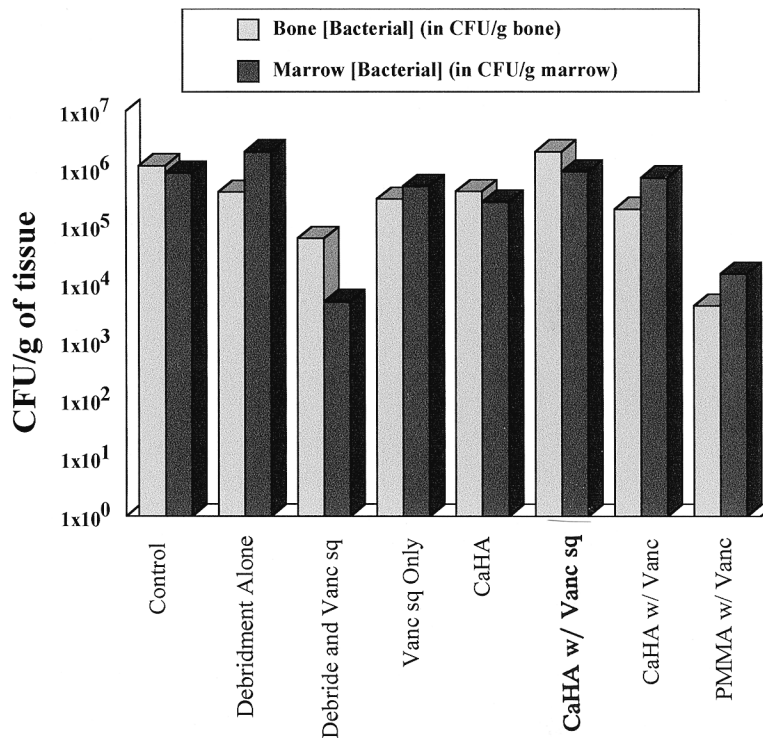


Fig 1. The mean colony forming unit levels detected in tibias of control and experimental groups after infection with 10^6 colony forming units of methicillin resistant *Staphylococcus aureus* and a 4-week treatment regimen are shown. Groups included Group One, Control ($n = 26$)—infected but untreated controls; Group Two, debridement alone ($n = 12$)—debridement surgery 2 weeks after infection; Group Three, debridement and subcutaneous vancomycin (Debride and Vanc sq) ($n = 8$)—debridement surgery (2 weeks after infection) and 4 weeks subcutaneous vancomycin administration at a dose of 30 mg/kg twice daily; Group Four, subcutaneous vancomycin only (Vanc sq only) ($n = 11$)—4 weeks subcutaneous vancomycin administration at a dose of 30 mg/kg twice daily starting 2 weeks after infection; Group Five, calcium hydroxyapatite (CaHA) ($n = 10$)—calcium hydroxyapatite material (without antibiotic impregnation) implanted into the dead space created by the debridement surgery (done 2 weeks after infection); Group Six, calcium hydroxyapatite and subcutaneous vancomycin (CaHA and Vanc sq) ($n = 8$)—hydroxyapatite material (without antibiotic impregnation) implanted into the debrided region and subcutaneous vancomycin treatment at a dose of 30 mg/kg twice daily for 28 days after debridement surgery; Group Seven, calcium hydroxyapatite impregnated with vancomycin (CaHA w/Vanc) ($n = 12$)—hydroxyapatite material (impregnated with vancomycin) implanted into the dead space left after the debridement surgery; Group Eight, polymethylmethacrylate impregnated with vancomycin (PMMA w/Vanc) ($n = 11$)—polymethylmethacrylate cement beads (impregnated with vancomycin) implanted into the dead space after debridement surgery.

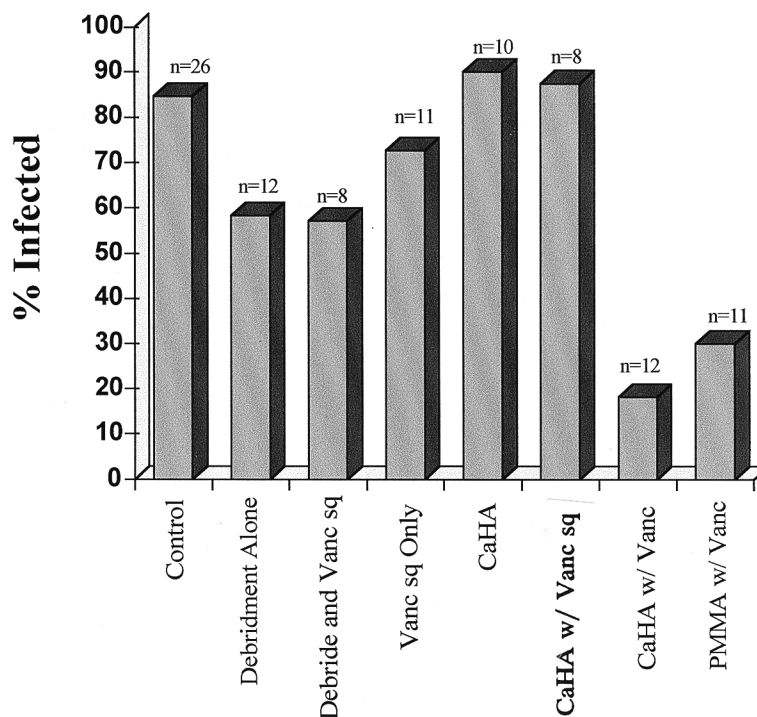


Fig 2. The percent of animals with positive cultures for *Staphylococcus aureus* detected in control and experimental groups after infection with 10^6 colony forming units of methicillin resistant *Staphylococcus aureus* and a 4 week treatment regimen are shown. Groups included Group One, Control ($n = 26$)—infected but untreated controls; Group Two, debridement alone ($n = 12$)—debridement surgery 2 weeks after infection; Group Three, debridement and subcutaneous vancomycin (Debride and Vanc sq) ($n = 8$)—debridement surgery (2 weeks after infection) and 4 weeks subcutaneous vancomycin administration at a dose of 30 mg/kg twice daily; Group Four, subcutaneous vancomycin only (Vanc sq only) ($n = 11$)—4 weeks subcutaneous vancomycin administration at a dose of 30 mg/kg twice daily starting 2 weeks after infection; Group Five, calcium hydroxyapatite (CaHA) ($n = 10$)—calcium hydroxyapatite material (without antibiotic impregnation) implanted into the dead space created by the debridement surgery (done 2 weeks after infection); Group Six, calcium hydroxyapatite and subcutaneous vancomycin (CaHA and Vanc sq) ($n = 8$)—hydroxyapatite material (without antibiotic impregnation) implanted into the debrided region and subcutaneous vancomycin treatment at a dose of 30 mg/kg twice daily for 28 days after debridement surgery; Group Seven, calcium hydroxyapatite impregnated with vancomycin (CaHA w/Vanc) ($n = 12$)—hydroxyapatite material (impregnated with vancomycin) implanted into the dead space left after the debridement surgery; Group Eight, polymethylmethacrylate impregnated with vancomycin (PMMA w/Vanc) ($n = 11$)—polymethylmethacrylate cement beads (impregnated with vancomycin) implanted into the dead space after debridement surgery.

with vancomycin) group and the rabbits that were treated with debridement followed by 4 weeks vancomycin administration (30 mg/kg, twice daily). Radiographs at sacrifice showed progressive osteomyelitis in the control groups and no worsening in the rabbits that were treated with antibiotic-impregnated hydroxyapatite.

DISCUSSION

In the current study, antibiotic-impregnated hydroxyapatite implant material showed significantly higher efficacy in reducing concentrations of *Staphylococcus aureus* in the tibia of rabbits to lower than detectable levels when

compared with all treatments with the exception of polymethylmethacrylate and the rabbits that were treated with debridement followed by 4 weeks vancomycin administration (30 mg/kg, twice daily). When compared with polymethylmethacrylate, the hydroxyapatite had approximately equal efficacy. However, an hydroxyapatite material impregnated with antibiotics may be better than polymethylmethacrylate beads and intravenous antibiotics in various ways, as mentioned previously. A significant difference between the antibiotic-impregnated calcium hydroxyapatite treated group and the group that was treated with debridement followed by 4 weeks vancomycin administration was not found. However, the small sample size of the debridement-vancomycin treated group ($n = 8$) may have prevented attaining significance.

Colony forming unit concentrations showed no significant differences between the experimental groups, with the exception of the groups of rabbits that received debridement with subcutaneous vancomycin and the polymethylmethacrylate beads impregnated with vancomycin. However, the more applicable data are from a comparison between percentages of rabbits infected for each of the treatment modalities. The classification of the study animals as infected or not infected after the treatment period more closely reflects the clinical setting because patients still infected would receive additional treatment regimens.

Generally, groups that received debridement surgeries had a lower percentage of infected rabbits at the end of the treatment period ($p \leq 0.05$). This is most likely attributable to the removal of the nidus of infection, the surrounding infected tissue, and the involucrum. Once these infected tissues were removed, the antibiotic or host immune system or both could more easily clear the infection.^{5,24} Subsequent treatment with parenteral antibiotic therapy additionally reduced the amount of those organisms. Groups that were treated with calcium hydroxyapatite, when not impregnated with antimicrobial agents (calcium hydroxyapatite alone and calcium hydroxyapatite with subcu-

taneous vancomycin), had an approximately equal or higher percentage of infected samples than infected nontreated controls. The reason for this exacerbation of the infection seen in the calcium hydroxyapatite implants when not impregnated with antibiotics is because the implant, once coated in host proteins, provides an excellent source of attachment for any bacteria remaining after debridement surgery.^{11,12,15,26} Once attached, the bacteria can form the glycocalyx, or slime layer, which protects the bacteria from normal host defenses and systemic antibiotics.^{7,8,13,28}

Calcium hydroxyapatite (impregnated with vancomycin) and polymethylmethacrylate (impregnated with vancomycin) were the lowest levels of percent infected with 18.2% and 30%, respectively. These levels are in accordance with levels reported in previous studies.^{6,20,37} Therefore, when calcium hydroxyapatite antibiotic-impregnated implants were used, the clearance of bacteria to undetectable levels in this group was statistically equivalent to the polymethylmethacrylate group ($p > 0.05$) and was significantly less than controls ($p < 0.05$). However, in a normal clinical setting, polymethylmethacrylate beads would have required secondary surgery to remove the implants, whereas the calcium hydroxyapatite was almost completely resorbed. In the current study, the authors inserted the calcium hydroxyapatite implant as one cohesive unit that filled the entire dead space created by debridement surgery. The use of the hydroxyapatite implant may have been more efficacious by compressing this new antibiotic-impregnated implant material into smaller beads. These beads would increase the surface area and allow for increased bioavailability for calcium resorption and antibiotic diffusion from the implant.

The calcium hydroxyapatite cement antibiotic delivery system worked as well as polymethylmethacrylate, the standard mode of antibiotic bead implantation. However, calcium hydroxyapatite does not require a secondary surgery for removal, making it the more attractive of the two options.

Acknowledgments

The authors thank Donna Milner Mader and Maureen Dawn Shirliff for manuscript preparation.

References

- Adams K, Couch L, Cierny G, et al: In vitro and in vivo evaluation of antibiotic diffusion from antibiotic-impregnated polymethylmethacrylate beads. *Clin Orthop* 278:244–252, 1992.
- Buchholz HW, Engelbrecht H: Uber die depotwirkung ieniger antibiotika bei vermischung mit dem kunstharz palacos [Depot effects of various antibiotics mixed with Palacos resins]. *Chirurgie* 41:511–515, 1970.
- Calhoun JH, Mader JT: Antibiotic beads in the management of surgical infections. *Am J Surg* 157:443–449, 1989.
- Calhoun JH, Mader JT: Treatment of osteomyelitis with a biodegradable antibiotic implant. *Clin Orthop* 341:206–214, 1997.
- Cierny GI, Mader JT: Management of adult osteomyelitis. *Surg Musculoskeletal System* 10:15–35, 1983.
- Cornell CN, Tyndall D, Waller S, et al: Treatment of experimental osteomyelitis with antibiotic-impregnated bone graft substitute. *J Orthop Res* 11:619–626, 1993.
- Darouiche RO, Dhir A, Miller AJ, et al: Vancomycin penetration into biofilm covering infected prostheses and effect on bacteria. *J Infect Dis* 170:720–723, 1994.
- Duguid IG, Evans E, Brown MR, et al: Effect of biofilm culture upon the susceptibility of *Staphylococcus epidermidis* to tobramycin. *J Antimicrob Chemother* 30:803–810, 1992.
- Ericsson HM, Sherris JC: Antibiotic sensitivity testing: Report of an international collaborative study. *Acta Pathol Microbiol Scand* 217(Suppl):1, 1971.
- Fitzgerald RHJ: Experimental osteomyelitis: Description of a canine model and the role of depot administration of antibiotics in the prevention and treatment of sepsis. *J Bone Joint Surg* 65A:371–380, 1983.
- Francois P, Vandaux P, Lew PD: Role of plasma and extracellular matrix proteins in the physiopathology of foreign body infections. *Ann Vasc Surg* 12:34–40, 1998.
- Gracia E, Fernandez A, Conchello P, et al: Adherence of *Staphylococcus aureus* slime-producing strain variants to biomaterials used in orthopaedic surgery. *Int Orthop* 21:46–51, 1997.
- Gristina AG, Hobgood CD, Webb LX, et al: Adhesive colonization of biomaterials and antibiotic resistance. *Biomaterials* 8:423–426, 1987.
- Henry SL, Galloway KP: Local antibacterial therapy for the management of orthopaedic infections: Pharmacokinetic considerations. *Clin Pharmacokinet* 29:36–45, 1995.
- Herrmann M, Vaudaux PE, Pittet D, et al: Fibronectin, fibrinogen, and laminin act as mediators of adherence of clinical staphylococcal isolates to foreign materials. *J Infect Dis* 158:693–701, 1988.
- Horowitz SM, Frondoza CG, Lennox DW: Effects of polymethylmethacrylate exposure upon macrophages. *J Orthop Res* 6:827–832, 1988.
- Isiklar ZU, Demirors H, Akpınar S, et al: Two-stage treatment of chronic staphylococcal orthopaedic implant-related infections using vancomycin impregnated PMMA spacer and rifampin containing antibiotic protocol. *Bull Hosp Jt Dis* 58:79–85, 1999.
- Josefsson G, Kolmert L: Prophylaxis with systematic antibiotics versus gentamicin bone cement in total hip arthroplasty: A ten-year survey of 1688 hips. *Clin Orthop* 292:210–214, 1993.
- Kanellakopoulou K, Giamarellos-Bourboulis EJ: Carrier systems for the local delivery of antibiotics in bone infections. *Drugs* 59:1223–1232, 2000.
- Korkusuz F, Uchida A, Shinto Y, et al: Experimental implant-related osteomyelitis treated by antibiotic-calcium hydroxyapatite ceramic composites. *J Bone Joint Surg* 75B:111–114, 1993.
- Mader JT: Animal models of osteomyelitis. *Am J Med* 78:213–217, 1985.
- Mader JT, Adams K: Comparative evaluation of daptomycin (LY146032) and vancomycin in the treatment of experimental methicillin-resistant *Staphylococcus aureus* osteomyelitis in rabbits. *Antimicrob Agents Chemother* 33:689–692, 1989.
- Mader JT, Calhoun J, Cobos J: In vitro evaluation of antibiotic diffusion from antibiotic-impregnated biodegradable beads and polymethylmethacrylate beads. *Antimicrob Agents Chemother* 41:415–418, 1997.
- Mader JT, Ortiz M, Calhoun JH: Update on the diagnosis and management of osteomyelitis. *Clin Podiatric Med Surg* 13:701–724, 1996.
- Mader JT, Wilson KJ: Comparative evaluation of cefamandole and cephalothin in the treatment of experimental *Staphylococcus aureus* osteomyelitis in rabbits. *J Bone Joint Surg* 65A:507–513, 1983.
- McDevitt D, Francois P, Vandaux P, et al: Molecular characterization of the clumping factor (fibrinogen receptor) of *Staphylococcus aureus*. *Mol Microbiol* 11:237–248, 1994.
- Norden CW: Experimental osteomyelitis: I. A description of the model. *J Infect Dis* 122:410–418, 1970.
- Oie S, Huang Y, Kamiya A, et al: Efficacy of disinfectants against biofilm cells of methicillin-resistant *Staphylococcus aureus*. *Microbios* 85:223–230, 1996.
- Ostermann PA, Seligson D, Henry SL: Local antibiotic therapy for severe open fractures: A review of 1085 consecutive cases. *J Bone Joint Surg* 77B:93–97, 1995.
- Ozaki T, Yoshitaka T, Kunisada T, et al: Vancomycin-impregnated polymethylmethacrylate beads for methicillin-resistant *Staphylococcus aureus* (MRSA) infection: Report of two cases. *J Orthop Sci* 3:163–168, 1998.
- Petty W: The effect of methylmethacrylate on bacterial phagocytosis and killing by human polymorphonuclear leukocytes. *J Bone Joint Surg* 60A:752–757, 1978.
- Petty W: The effect of methylmethacrylate on chemotaxis of polymorphonuclear leukocytes. *J Bone Joint Surg* 60A:492–498, 1978.
- Petty W: The effect of methylmethacrylate on the bacterial inhibiting properties of normal human serum. *Clin Orthop* 132:266–278, 1978.

34. Petty W, Caldwell JR: The effect of methylmethacrylate on complement activity. *Clin Orthop* 128:354–359, 1977.
35. Salvati EA, Callaghan JJ, Brause BD, Klein RF, Small RD: Reimplantation in infection: Elution of gentamicin from cement and beads. *Clin Orthop* 207:83–93, 1986.
36. Shirtliff ME, Mader JT: The Rabbit Model of Bacterial Osteomyelitis of the Tibia. In Zak O, Sande MA (eds). *Handbook of Animal Models of Infection*. London, Academic Press Ltd 581–591, 1999.
37. Solberg BD, Gutow AP, Baumgaertner MR: Efficacy of gentamycin-impregnated resorbable hydroxyapatite cement in treating osteomyelitis in a rat model. *J Orthop Trauma* 13:102–106, 1999.
38. Stemberger A, Grimm H, Bader F, et al: Local treatment of bone and soft tissue infections with the collagen-gentamicin sponge. *Eur J Surg* 578(Suppl):17–26, 1997.
39. Wachol-Drewek Z, Pfeiffer M, Scholl E: Comparative investigation of drug delivery of collagen implants saturated in antibiotic solutions and a sponge containing gentamicin. *Biomaterials* 17:1733–1738, 1996.
40. Wahlig H: Gentamicin-PMMA beads: A drug delivery system in the treatment of chronic bone and soft tissue infections. *J Antimicrob Chemother* 10:463–465, 1982. Letter.
41. Wahlig H, Dingeldein E: Antibiotics and bone cements: Experimental and clinical long-term observations. *Acta Orthop Scand* 51:49–56, 1980.
42. Wahlig H, Dingeldein E, Bergmann R, et al: The release of gentamicin from polymethylmethacrylate beads: An experimental and pharmacokinetic study. *J Bone Joint Surg* 60B:270–275, 1978.
43. Wahlig H, Dingeldein E, Buchholz HW, et al: Pharmacokinetic study of gentamicin-loaded cement in total hip replacements: Comparative effects of varying dosage. *J Bone Joint Surg* 66B:175–179, 1984.
44. Wilson KJ, Cierny G, Adams KR, et al: Comparative evaluation of the diffusion of tobramycin and cefotaxime out of antibiotic-impregnated polymethylmethacrylate beads. *J Orthop Res* 6:279–286, 1988.
45. Wilson KJ, Mader JT: Concentrations of vancomycin in bone and serum of normal rabbits and those with osteomyelitis. *Antimicrob Agents Chemother* 25:140–141, 1984.